

DISTRICT TWELVE MEDICAL EXAMINER

2001 Siesta Drive, Suite 302, Sarasota, FL 34239-2100 • Phone: (941) 361-6909 Fax: (941) 361-6914

CHIEF MEDICAL EXAMINER
Russell S. Vega, M.D.

DEPUTY CHIEF MEDICAL EXAMINER
Wilson A. Broussard Jr., M.D.

CHIEF INVESTIGATOR
Abby Andrus

DIRECTOR OF OPERATIONS
David Winterhalter

ASSOCIATE MEDICAL EXAMINERS
Suzanne R. Utley, M.D.
Leszek Chrostowski, M.D.

INVESTIGATORS
Ron Busbee, Jr. - Kristen Cavener
Lora Kenniff - Olivia Loveridge
Michael A. Rogers - Shawn C. Walker

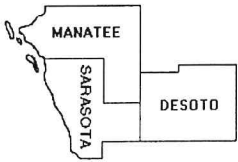
21-02238, Brian Laundrie

Medical Examiner Reports

Included in this packet are the following Medical Examiner Reports and Related Documents:

1. Investigator Case Summary (5 pages)
2. Medical Examiner Report of Scene Investigation (4 pages)
3. Medical Examiner Report of Autopsy (6 pages)
4. Consultation: Report of Osteological Examination (23 pages)
5. Laboratory Report: DNA Analysis (5 pages)
6. Consultation: Odontologic Forensic Identification Report (2 pages)

Note: Florida Statute 406.135 explicitly prohibits the release of autopsy photos by the Medical Examiner as part of routine public records requests. Accordingly, the photographs that were part of the original Report of Osteological Examination, pages 6-11, have been redacted.



DISTRICT TWELVE MEDICAL EXAMINER

2001 SIESTA DRIVE, SUITE 302, SARASOTA, FL 34239-5200
PHONE: (941) 361-6909 FAX: (941) 361-6914

CASE SUMMARY

CASE # 21-02238

DECEDENT	BRIAN CHRISTOPHER LAUNDRIE	COUNTY	SARASOTA
DATE OF DEATH	FOUND: OCTOBER 20, 2021	AGE	23
MEDICAL EXAMINER	WILSON A. BROUSSARD, JR., M.D.	RACE	WHITE
INVESTIGATOR	RONALD L. BUSBEE, JR.	SEX	MALE

RELATED CASES

NAME:

CASE NUMBER:

On October 20, 2021 at 0930 hours, I was contacted by Sergeant Fortuno from the North Port Police Department in reference to apparent human skeletal remains. The remains were discovered in the Carlton Reserve, north of the Myakkahatchee Creek Environmental Park, located at 6968 Reistertown Road in North Port.

Sergeant Fortuno advised that a massive search had been ongoing in the Carlton Reserve for several weeks by multiple agencies for 23-year-old, white male, Brian Christopher Laundrie (DOB – November 18, 1997). On October 20, 2021 at approximately 0820 hours, search groups found a backpack and shoes that were identified as belonging to Brian Laundrie. The personal belongings were surrounded by apparent skeletal human remains that were scattered on top of the dirt ground. I was informed that the Evidence Response Team from the Federal Bureau of Investigation, along with cadaver and electronic detection dogs were responding to the scene to assist in locating additional human remains.

I contacted Dr. Vega, Dr. Broussard, Director Winterhalter, and Chief Investigator Andrus and provided them with the above information.

At 1245 hours, same date, I was contacted by Detective Keller from the North Port Police Department who advised that he was the lead investigator for their agency. The apparent human remains were located at latitude 27.127698 north and longitude -82.192652 west, which was within the Carlton Reserve.

At 1400 hours, same date, Director Winterhalter contacted Forensic Odontologist Dr. Nancy Havens, and requested forensic odontology consultation for October 21, 2021.

At 1605 hours, same date, I was contacted by Sergeant Fortuno who advised that they were requesting the Office of the District Twelve Medical Examiner to respond.

At 1620 hours, same date, Chief Investigator Andrus contacted Dr. Heather Walsh-Haney and Dr. Maranda Kles and requested an anthropology consultation to assist with the examination of the skeletal remains at the scene the following day.

At 1700 hours, same date, Chief Investigator Andrus, Investigator Cavener, Investigator Loveridge, and I arrived on scene. We were transported to the location of the apparent human remains. Upon arrival, we met with the Kerrie Harvey, Team Leader of the Federal Bureau of Investigation – Evidence Response Team, who walked us through the scene. Team Leader Harvey informed us that the search area was previously under approximately three feet of water, which was indicated by the water line upon the surrounding trees. The search area was divided into the “main” scene and a “secondary” scene. Both scenes were marked with orange flags that indicated apparent human and/or animal remains and red flags that indicated personal effects. I photographed the scene as I observed with a Nikon digital camera.

At 1730 hours, same date, Dr. Vega and Dr. Broussard arrived on scene and examined the skeletal remains. Please refer to Dr. Broussard’s report for further details.

The scene was north of the Myakkahatchee Creek Environmental Park, within the Carlton Reserve and west of the Big Slough Canal. The scene included trees and overgrown vegetation that had total exposure to the outside elements. A winding, walking and vehicular trail ran in a north/northeast direction up to and through the scene. The skeletal remains and personal effects were in plain sight and scattered upon the dirt ground.

The “main” scene contained human remains that included a right and left scapula, a right humerus, a left and right femur, two tibias, two fibulas, two clavicles, two pelvis, one right ulna, one right radius, a sacrum, multiple ribs, multiple skull fragments along with the maxilla and mandible, and approximately twenty-five vertebrae (cervical, thoracic, and lumbar). Dr. Broussard confirmed the remains in this area to be human.

The “main” scene also contained personal effects that included a pair of green shorts with a green belt, two slip-on shoes, a backpack with unknown contents, a white metal ring, and an unknown type of handgun (snub-nose revolver).

The “secondary” scene contained skeletal animal remains, a handwritten half note, and a hat with the logo “MOAB Coffee Roasters”.

I was informed that a drybag was located that contained a journal, along with a wooden box that contained a small notebook and a photographic picture of Brian Laundrie. I was advised that there were additional photographic pictures, but the contents were undisclosed to me at that time.

At 2000 hours, same date, all personnel from the District Twelve Medical Examiner cleared the scene.

Investigator Cavener transported skeletal human remains that included cranial bones, maxilla with existing teeth, and mandible with existing teeth that were processed by the Evidence Response Team of the Federal Bureau of Investigation to the Sarasota Medical Examiner Facility for potential identification purposes. The remains were logged into the morgue at 2221 hours, same date.

On October 21, 2021 at 0800 hours, Director Winterhalter met Dr. Nancy Havens, Forensic Odontologist, at the Sarasota Medical Examiner Facility to assist with the forensic odontology consultation. Please refer to her report for additional details.

At 0906 hours, same date, I contacted Dr. Udeshi from Sayville Family Dentistry in New York and requested the decedent's dental records/radiographs, along with corresponding physician notes. I learned that agents with the Federal Bureau of Investigation were able to obtain the dental records/radiographs on behalf of the District Twelve Medical Examiner. Upon receiving the records/radiographs, they were provided to Dr. Havens.

At 1010 hours, same date, I was contacted by Detective Keller who advised that they believed they located additional bones from the decedent's left arm bones within the "main" scene.

At 1300 hours, same date, Chief Investigator Andrus, Investigator Walker, and I arrived on scene.

At 1300 hours, same date, Forensic Anthropologist Dr. Walsh-Haney and Dr. Kles arrived on scene, at which time, they were walked through the scene.

At 1315 hours, same date, Dr. Broussard arrived on scene.

We made contact with Kerrie Harvey, Team Leader of the Federal Bureau of Investigation – Evidence Response Team, who advised that the "main" scene was divided into three zones which were designated for sifting purposes in search for additional human remains. Zone 1 contained remains of the upper torso, upper extremities, and head. Zone 2 contained remains of the lower vertebrae and sacrum. Zone 3 contained remains of the left arm bones.

A systematic search was conducted by all agencies involved for the recovery of additional human remains.

At 1605 hours, same date, I contacted Brasota Services and requested removal of the remains from the scene to the Sarasota Medical Examiner Facility.

At 1620 hours, same date, I was contacted by Director Winterhalter who advised that Forensic Odontologist, Dr. Nancy Havens, positively identified the human remains as 23-year-old, white male, Brian Christopher Laundrie (DOB – November 18, 1997) through the comparison of the antemortem, dental radiographs, and dentition (including postmortem radiographs) to known dental records.

At 1625 hours, same date, a projectile was located near Zone 2 of the "main" scene by the Evidence Recovery Team of the Federal Bureau of Investigation by utilizing a metal detector.

All additional, human and animal remains, along with personal effects were collected and inventoried on-site by the Evidence Response Team of the Federal Bureau of Investigation.

Please refer to the reports from the North Port Police Department (reference case # 21-054011) and the Federal Bureau of Investigation (reference case # 70A-DN-3494764) for further details. The Federal Bureau of Investigation case represented a crime on government reservation and crime of violence that involved the decedent.

At 1700 hours, same date, Forensic Anthropologists Dr. Walsh-Haney and Dr. Kles cleared the scene.

At 1745 hours, same date, Dr. Broussard, Chief Investigator Andrus, Investigator Walker, and I cleared the scene. Dr. Broussard advised that a skeletal examination and inventory would be scheduled for October 22, 2021.

On October 22, 2021 at 0900 hours, Dr. Vega, Dr. Broussard, Dr. Kles, Investigator Rogers, and I met with Dr. Walsh-Haney at the Sarasota Medical Examiner Facility to conduct an inventory and photograph the skeletal remains with a Nikon digital camera. Please refer to Dr. Walsh-Haney's report for further details. Dr. Walsh-Haney transported the remains to the Office of the District 20 Medical Examiner for anthropological examination and reconstruction.

Detective Keller and Lead Agent Bush (Federal Bureau of Investigation) arrived at the Sarasota Medical Examiner Facility. Detective Keller reported that the decedent's sister informed that the decedent was right-hand dominant. Detective Keller informed us that the decedent was last known alive on September 13, 2021 when he left his residence to go hiking in the Carlton Reserve, but the decedent did not return home. On September 14, 2021, the decedent's vehicle was located in the parking lot of the Myakkahatchee Creek Environmental Park. On September 17, 2021, the decedent was reported to the North Port Police Department as a missing person. During this time period, it rained for several days which caused portions of the Carlton Reserve to be flooded. On October 07, 2021, the flooding receded to the point where the Carlton Reserve was hikeable again.

On October 26, 2021 at 1200 hours, I contacted the decedent's parents, Christopher and Roberta Landrie, and explained the District Twelve Medical Examiner's involvement. I directed Mr. and Mrs. Landrie to contact the North Port Police Department and the Federal Bureau of Investigation for further information in regards to the autopsy results and additional investigative information. Mr. and Mrs. Landrie informed me that their son was very healthy and had no known medical history. The decedent did not take any medications and had no known primary care physician. When I asked about the decedent's social history, Mr. and Mrs. Landrie stated that they did not want to provide that information.

At 1326 hours, same date, I was contacted by Detective Keller who advised that Lead Agent Bush from the Federal Bureau of Investigation notified him that the firearm collected at the scene was evaluated. The firearm was a European American Arms, .38 special (on barrel), .357 magnum (other side of barrel). Based upon the markings and appearance, the firearm was a Windicator revolver. The cylinder contained two live rounds and one spent round of ammunition.

On November 09, 2021 at 1100 hours, Dr. Walsh-Haney returned the decedent's remains to the Office of the District Twelve Medical Examiner. I photographed the reconstructed remains with a Nikon digital camera.

On November 11, 2021 at 1030 hours, at the request of the Federal Bureau of Investigation personnel, two sections of femur bone and a tooth (molar) were retained for DNA analysis. There were transported to the Pinellas County Forensic Laboratory and delivered by myself at 1055 hours, same date.

On November 19, 2021 at 1313 hours, I received a Laboratory Report – DNA Analysis, via electronic email, from Tina Jastrzemski of the Pinellas County Forensic Laboratory. The notification was a confirmation on the identity of the human skeletal remains on this case. The remains were identified as 23-year-old, white male, Brian Christopher Landrie (DOB – November 18, 1997). The notification was signed by Beth Ordeman, DNA Analyst.

The above additional information was immediately provided to Dr. Vega and Dr. Broussard for further review.

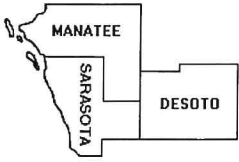
On November 22, 2021 at 0940 hours, I contacted Lead Agent Bush and discussed the decedent's positive identification through DNA analysis.

At 1200 hours, same date, I contacted Detective Keller and discussed the decedent's positive identification through DNA analysis.

On November 23, 2021 at 1250 hours, I contacted the decedent's parents, Christopher and Roberta Landrie, and discussed their son's death certificate certification.

A handwritten signature in black ink, appearing to read "Ron Busbee, Jr.", with a stylized flourish at the end.

Investigator Ronald L. Busbee, Jr.



DISTRICT TWELVE MEDICAL EXAMINER

2001 SIESTA DRIVE, SUITE 302, SARASOTA, FL 34239-5200
PHONE: (941) 361-6909 FAX: (941) 361-6914

MEDICAL EXAMINER REPORT

CASE # 21-02238

DECEDENT	BRIAN CHRISTOPHER LAUNDRIE	COUNTY	SARASOTA
	<small>First, Middle, Last</small>	DOD	10/20/2021
EXAMINATION	Date: _____ Time: _____ Place: _____	AGE	23
MEDICAL EXAMINER	WILSON A. BROUSSARD, JR., M.D.	RACE	WHITE
INVESTIGATOR	RONALD L. BUSBEE, JR.	SEX	MALE

SCENE INVESTIGATION

Date: 10/20/2021 and 10/21/2021

Location: Carlton Reserve, 6968 Reisterstown Road, North Port, Florida

Time Arrived at Scene: 10/20/21 at 1730 hours, 10/21/21 at 1315 hours

Law Enforcement Agencies: North Port Police Department and the Federal Bureau of Investigation

Lead Investigators: Detective Keller of North Port Police Department, Special Agent Loretta Bush of the Federal Bureau of Investigation

INITIAL INFORMATION:

The North Port Police Department contacted on-call Investigator Ron Busbee at 0930 hours on October 20, indicating that they believe that the remains of the missing individual Brian Christopher Laundrie had been found in an area where searches had been initiated several weeks prior. Reportedly in the morning hours, North Port Police Department had groups of personnel that discovered bones and personal belongings consistent with Brian C. Laundrie. The Federal Bureau of Investigation Evidence Response Team, along with cadaver dogs and other search groups, were continuing to lay out the area where the remains were found. Our assistance was not requested at this point. Later in the day, at 1605 hours, Investigator Busbee was contacted to request our response to the scene. The remains were reportedly located at latitude 27.127698N and longitude -82.192652W inside the Carlton Reserve. We were told to meet at the Myakkahatchee Creek Environmental Park. Upon arrival at the Myakkahatchee Creek Environmental Park, police personnel transported us approximately 1 mile from the environmental park entrance into the Carlton Reserve where the remains had been found.

OBSERVATION OF SURROUNDINGS AND REMAINS:**Day One.**

The late afternoon is warm and dry. We are transported from the park entrance to the scene (above listed coordinates) in an ATV which ultimately headed in north, northeast direction for approximately a mile. The scene is a wooded low-lying area with multiple patches of trees with underbrush mixed with some areas of open canopy. The ground is moderately dry with lower areas having both damp and wet spots. Upon arrival at the scene, several tarps and canopies had been set up by the law enforcement agencies. We are briefed at the scene by Detective Keller of North Port Police Department along with Kerrie Harvey, the leader of the Federal Bureau of Investigation's Evidence Response Team. We are told upon arrival that the area where the remains had been located was previously under up to, and possibly more than 3 feet of water for an extended period of time. Initially the search area had been divided into a main scene (above listed coordinates) and secondary scene (generally 100 to 250 feet east of the main scene). Human remains, animal remains and evidence had been marked with labeled flags for documentation. Adjacent to the main scene area, a small currently dry stream bed with a slightly, but noticeably deeper elevation is oriented in a general east/west direction.

Walking the main scene area with Detective Keller disclosed human remains including the right and left scapulae, right humerus, right femur, two tibiae, two fibulae, two clavicles, two pelvic bones, the sacrum, one right ulna, one right radius, and multiple ribs. Also, multiple fragments of cranium and skull along with a generally intact mandible with attached teeth and the lower aspect of the maxilla with attached teeth are noted. Cervical, thoracic, and lumbar vertebrae are also located nearby. Within the main scene area several personnel effects are pointed out including a pair of green shorts in the leaf debris approximately 20 feet south from the cranial fragments previously described. Two slip-on shoes approximately 10 feet apart (from each other), a white metal ring, and a short-barrel revolver handgun with extensive rust are noted on the ground near the previously described cranial fragments.

Within 10 to 20 feet west of the larger cranial fragments is a green backpack with associated gear including a tent and flares. The tent was still in the backpack and was not set up (pitched). Approximately 250 feet east in what was initially designated the secondary scene area, multiple animal bones are identified. A piece of paper and a red hat with the logo "Moab Coffee Roasters" are noted in a grassy area. We are informed that an apparent dry bag was located in another area approximately 250 feet southwest of the main area which contained a journal along with a wooden box that contained a small notebook and photographs, some of the photos include Brian Landrie.

Prior to leaving the scene, arrangements are made for human remains samples (bags) labeled HR1, HR3, HR2A, HR2B, HR4, HR5, and HR7 to be transported to the Sarasota Medical Examiner Facility that night. HR1 contained the maxilla/palate with nine teeth and HR2A contained the mandible with fifteen teeth. These are to be examined as soon as arrangements can be made with our forensic odontologist for potential identification match. These evidence bags with the previously described labels are transported on 10/20/21 by Investigator Kristen Cavener to the Sarasota Medical Examiner Facility. I cleared the scene from the park entrance at 2000 hours. See separate Case Summary Report for positive identification information.

Day 2.

On 10/21/2021 at 1315 I arrived back at the scene, parking at the Myakkahatchee Creek Environmental Park to be transported to the remains area. Fifteen minutes prior to my arrival, Investigators Andrus, Walker, and Busbee along with Forensic Anthropologists Dr. Heather Walsh-Haney and Dr. Maranda Kles also arrived at the scene. The forensic anthropologists were invited at our request for assistance in identification and collection of any further human remains.

The Federal Bureau of Investigation Evidence Response Team has collected all bones identified the evening prior and labeled them into evidence bags after documenting, logging, and photographing each bone and/or evidence collected. Evidence markers and bags designated as "HR" contained remains preliminary identified as human. Team Leader Harvey from the Evidence Response Team advised that the initial "main" scene area as discussed from the prior evening has been divided into three zones (Zones 1, 2, and 3). Zone 1 contained the remains including those of the upper torso, right upper and both lower extremities, and head. Zone 2 contained remains including several lower vertebrae and the sacrum, and Zone 3 had left upper extremity bones.

A systematic re-search of all zones is conducted for additional human remains. In the north area of Zone 1, near the base of a large tree and the dry east/west oriented creek bed (near where the majority of the bones were found, including the craniofacial bones, the handgun and a white metal ring), a surface dig is done by the Medical Examiner Investigators, Forensic Anthropologists, Evidence Response Team members and myself. Each zone is excavated to approximately 6 cm deep using trowels and shovels. All the leaf debris and excavated dirt were placed into 5-gallon plastic buckets and then sifted through 1/4-inch screens onto a large blue tarpaulin which was set up nearby. This process led to finding nine additional cranial fragments, two upper central incisors, and one hand phalanx (all from zone 1). These are added to the remains collected and logged in earlier.

At approximately 1625 one of the members of the FBI Evidence Response Team discovered a projectile with her metal detector approximately 50-60 feet south of the area where the skull fragments and handgun were initially located. This was in approximately 6 inches of dirt.

SCENE IMPRESSION/ACTIONS TAKEN:

The remainder of the skeletal remains are inventoried by the Federal Bureau of Investigation, packaged as evidence, released to the Medical Examiner and transported back to the Myakkahatchee Creek Environmental Park area.


From the park staging area, packaged bags from scene day 2 including HR6-HR103 (with the exception of HR34 and HR35 which were confirmed as animal remains) are transported to the Sarasota Medical Examiner Facility by Brasota Services for further examination.

The scene is consistent with skeletal remains of a single individual that appear consistent with a moderately young male. The cranial fragmentation and presence of a handgun are consistent with

a gunshot injury of the head. Full osteologic examination and cranial reconstruction will be performed to identify potential specific gunshot evidence. All non-human remains evidence is collected by the F.B.I. for further workup/evaluation. Overall documented geographic evidence with data point/location diagrams and reports are to be completed by the F.B.I.

I cleared the scene at 1745 from the park entrance.

NOTE: The foregoing is of a preliminary nature and subject to modifications pending additional information and/or investigation.

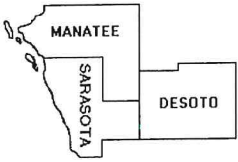


Wilson A. Broussard, Jr., M.D.
Deputy Chief Medical Examiner

11/23/21
Date

WAB:dl

11/08/21



DISTRICT TWELVE MEDICAL EXAMINER

2001 SIESTA DRIVE, SUITE 302, SARASOTA, FL 34239-5200
PHONE: (941) 361-6909 FAX: (941) 361-6914

MEDICAL EXAMINER REPORT

CASE # 21-02238

DECEDENT	BRIAN CHRISTOPHER LAUNDRIE	COUNTY	SARASOTA
	<small>First, Middle, Last</small>	DOD	10/20/2021
EXAMINATION	Date: 10/22/21 Time: 9:00 AM Place: SMEF	AGE	23
MEDICAL EXAMINER	WILSON A. BROUSSARD, JR., M.D.	RACE	WHITE
INVESTIGATOR	RONALD L. BUSBEE, JR.	SEX	MALE
IN ATTENDANCE	DR. HEATHER WALSH-HANEY, DR. MARANDA KLES		

REPORT OF AUTOPSY


SUMMARY OF AUTOPSY/SKELETAL REMAINS FINDINGS:

- I. Skeletal Remains-Single Individual
 - A. Scattered Remains (bones without soft tissue), most with Post-mortem Scavenging/Carnivore Activity (near complete skeleton)
 - B. Positively Identified with Antemortem Dental Radiograph and Record Comparison
 - C. Gunshot Wound of the Head with extensive, associated Craniofacial Fractures

TOXICOLOGY: Please refer to the separate toxicology report.

CAUSE OF DEATH: Gunshot Wound of the Head

MANNER OF DEATH: Suicide (Shot self with handgun)


 Wilson A. Broussard, Jr., M.D.
 Deputy Chief Medical Examiner

11/23/21
 Date

WAB:dl
11/08/21

GENERAL DESCRIPTION:

The skeletal remains are consistent with a young adult male. The vast majority of the skeleton has been recovered. The level of skeletonization is generally complete but for minimal areas of adipocere-like white sheen on some of the vertebrae. No soft tissue remains but for minimal partially calcified costal cartilage at the anterior aspects of some of the lower ribs. Multiple long bones including bones of the arms and legs all disclose carnivore predation activity characterized by gnawing and chewing, mostly on the distal ends of the long bones. The cranium is in multiple pieces and fragments as will be described below. Most of the bones have dark discoloration consistent with the dark soil material where the bones were recovered.

SKELETAL INVENTORY:

Bones are designated HR1 (HR = Human Remains) through HR103 as packaged by the Evidence Response Team of the Federal Bureau of Investigation. The only exceptions to a routine chronologic numbering system are **1)** there is an HR2A and HR2B designation and **2)** HR34 and HR35 were initially designated as human remains, but were later confirmed as non-human and kept by the F.B.I. Evidence Response Team at the recovery scene. HR81 and 82 are non-human remains (non-human ribs) confirmed as such during autopsy/skeletal survey examination.

HR1 - right and left maxilla with the right and left palatine bones initially examined with 9 teeth.
HR2A – mandible with 15 teeth
HR2B – left sphenoid bone with portion of the temporal bone fragmented
HR3 – occipital cranial piece with some left parietal bone attached
HR4 – cranial piece with portions of the left and right parietal bone, occipital bone, right temporal bone, and sphenoid bones
HR5 – frontal bone fragment with some partial left and right parietal bones
HR7 – portion of frontal bone with left parietal bone attached
HR6 – left scapula
HR8 – left clavicle
HR9 – right hand metacarpal
HR10 – cervical vertebra 7
HR11 – intermediate hand phalanges
HR12 – single cervical vertebra (3-6)
HR13 – proximal hand phalanx
HR14, HR15, HR16 – three left ribs
HR17 – partial right maxilla with right sphenoid and right temporal bone and portions of the right zygomatic bone as a single skull fragment
HR18 – single right rib
HR19, HR20, HR21 –three left ribs

HR22 – sphenoid bone fragment
HR23 – single right rib
HR24 – right 1st rib, two other right ribs, and the manubrium sternum
HR25, HR26 – single right ribs
HR27 – intermediate hand phalanx
HR28 – right metacarpal bone
HR29, HR30 – the two pelvic bones (left and right os coxae, respectively)
HR31 – left rib
HR32 – right metacarpal
HR33 – two right ribs and the sternal body
HR36, HR37, HR38, HR39, HR40 – individual cervical vertebrae
HR41, HR42, HR43 – individual left ribs
HR44 – proximal foot phalanx
HR45 – right 1st metatarsal
HR46 – left calcaneus
HR47, HR48 – proximal and intermediate hand phalanges
HR49 – right 12th rib
HR50 – right rib
HR51 – left rib
HR52, HR53, HR54, HR55 – six thoracic vertebrae
HR56 – thoracic vertebra 12 and lumbar vertebrae 1, 2, and 3
HR57, HR58 – right metatarsals
HR59 – left metatarsal
HR60 – lumbar vertebra 5
HR61 – lumbar vertebrae 3 and 4
HR62 – right clavicle
HR63 – right rib
HR64 – thoracic vertebra 11 and two other thoracic vertebrae to be designated
HR65 – thoracic vertebrae 9 and 10
HR66 – sacrum with coccyx
HR67 – proximal hand phalanx
HR68 – metacarpal
HR69 – right radius
HR70 – right ulna
HR71, HR72 – metacarpal and metatarsal, respectively
HR73 – fibula
HR74 – cuneiform bone
HR75 – metacarpal
HR76 – metatarsal
HR77 – right femur
HR78 – fibula
HR79 – right tibia
HR80 – left femur
HR81, HR82 – non-human ribs
HR83 – right humerus
HR84 – proximal hand phalanx

HR85 – left ulna
HR86 – left humerus
HR87 – left tibia
HR88 – right scapula
HR89 – left radius
HR90 – cranial fragments
HR91 – cranial fragments
HR92 – cranial fragments
HR93 – left 1st rib
HR94 – cranial piece with nasal, maxillary, and left zygomatic bone fragments
HR95, HR96 – cranial fragments
HR97 – temporal cranial fragment
HR98, HR99, HR100 – cranial fragments
HR101 – left temporal cranial fragment
HR102 – multiple cranial fragments
HR103 – multiple cranial fragments, two upper incisors, and one distal hand phalanx

Radiographs disclose no metallic fragments or densely radiopaque material consistent with foreign bodies.

In summary, the vast majority of skeleton is recovered. The cranium is extensively fragmented with the mandible generally intact and the lower aspect of the maxilla generally intact, each with some teeth present as described. Missing bones include one mandibular tooth, five maxillary teeth, up to five craniofacial bone fragments with a moderately large area of the left temporal, lower left parietal, and superior wing of the left sphenoid bone absent. Also absent are the hyoid bone and thyroid and cricoid cartilages. The xiphoid process is absent. The ethmoid and lacrimal bones are absent as are both patellae. For completeness and quantity of tarsals, metatarsals, phalanges (and all bones), please refer to the separate Osteologic Examination.

EVIDENCE OF INJURY (Peri and Postmortem):

As previously mentioned, skeletonization, total soft tissue decomposition, and moderate to extensive animal predation are noted. Most of the distal long bones have moderately extensive carnivore activity evidenced by multiple gouging and gnawing marks. These areas are consistent with carnivores and/or omnivores including canines such as feral dogs and coyotes along with rodents and raccoons.

The cranium will be reconstructed for further evaluation along with a full osteologic exam for more precise changes and examination. The extensive fragmentation with comminuted intersecting skull fractures is consistent with a gunshot wound of the head.

WAB:dl

11/08/21

POST RECONSTRUCTION CRANIAL EXAMINATION (11/09/2021):

The cranial bones recovered, including 27 cranial fragments of various sizes, along with the mandible, have been reconstructed. Eight additional small fragments (thin sinus fragments) were not reconstructed. The reconstructed skull is near complete having the majority of the major cranial bones and creates a clear picture of perimortem trauma to be described below:

EVIDENCE OF INJURY:

Perforating Gunshot Wound of Head:

In summary, extensive fracturing including comminuted and intersecting linear and basilar fractures with associated cranial fragmentation is consistent with gunshot wound trauma. Evidence of a single perforating gunshot wound entering the left temporal cranium and exiting the right middle inferior parietal cranium just above the temporal bone (squamous suture) is identified.

The gunshot wound enters the left side of the head causing an area of extensive fracturing where the majority of the left temporal bone is absent along with extreme inferior aspects of the left parietal bone and portions of the posterior left sphenoid wing. A 5.5 by 5.0 cm area of bone defect (absence) is noted without definitive circular or semicircular defect and/or beveling (due to bone absence). The presumed exact entrance point is centered in this defect and is estimated at approximately 5.8 cm below the top of the cranium, 5.5 cm above the left external auditory canal and 6.0 cm left of midline.

The exit wound is located on the right middle inferior parietal bone, just above the apex of the temporal bone and is measured 4.5 cm below the top of the cranium, 5.5 cm above the right external auditory canal and 6.0 cm right of midline. The exit perforation is near circumferential, measures 11 to 12 mm in diameter (inner table) and has clear outer table beveling. No gunfire associated bone discolorations (soot or lead wipe) are noted. On the superior aspect of the exit wound is a 1.0 by 0.7 cm missing fragment of parietal bone.

Therefore, the overall pathway or trajectory of the gunshot wound is left to right, very slightly upward and having little to no significant front/back deviation.

Associated Fracture/s Description/s:

Associated with the gunshot wound are multiple linear intersecting fractures including:

- 1) a 5.0 cm fracture from the entrance fracture/defect to the superior left orbit.
- 2) a 19 cm linear fracture from the upper left sphenoid bone, across the left frontal bone, across the coronal suture and ends as it intersects a fracture at the medial-posterior left parietal bone.

3) small radiating fractures emanating from the entrance defect are noted of the adjacent left parietal bone.

4) a 17 cm linear fracture is noted of the upper posterior aspect of the entrance fracture defect, crossing the mid parietal bones (through the sagittal suture) and ultimately intersecting fractures associated with the exit defect on the right parietal bone.

5) an 18 cm linear fracture intersects the above described 17 cm parietal fracture on the left mid parietal area and continues medially and inferiorly (through the lambdoidal suture) left of midline, ultimately to the medial basilar aspect of the left occipital bone.

6) on the right side of the cranium adjacent to the exit defect are (3 cm to 5 cm) radiating fractures, above, posterior and anterior to the perforation of the right inferior mid parietal bone.

7) a partly elevated 4.2 by 2.2 cm wedged fracture is adjacent and superior to a larger linear fracture which intersects the posterior right squamous suture, crosses the mid parietal bone, crosses the coronal suture and ends near the right superior orbital area.

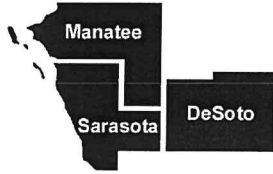8) other fractures include 9.5 and 7.5 cm fractures of the right frontal bone (which communicate with the previously described right parietal/frontal fracture).

9) the nasal bone is horizontally fractured and a piece of the right sphenoid bone is absent.

Specimens: Costochondral cartilage and a femoral bone segment with associated internal marrow are sent for potential toxicologic analysis. Femoral bone segments, and a molar tooth are retained for Law Enforcement for potential DNA analysis.

For complete anthropologic examination please refer to the separate, attached Osteologic Examination Report.

WAB:wab
11/16/2021



DISTRICT TWELVE MEDICAL EXAMINER

2001 Siesta Drive, Suite 302, Sarasota, FL 34239-2100 - Phone: (941) 361-6909 Fax: (941) 361-6914

TOXICOLOGY TESTING RESULTS

Decedent Information: Case #: 21-02238

Name: Brian Landrie

Race: White

Gender: Male

Age: 23 Years

Specimen collected and submitted by: BROUSSARD, M.D., Wilson A

University of Florida Toxicology		4800 SW 35th Drive		
		Gainesville, FL 32608		
		Tel: (352) 265-0680 Fax: (352) 265-9904		
Test	Specimen	Substance	Result	Date
Comprehensive Drug Screen	Bone, right proximal femur	NA	None Detected_	2/4/2022
Comprehensive Drug Screen	OTHER, costal cartilage	NA	None Detected_	2/4/2022

REPORT OF OSTEOLOGICAL EXAMINATION

DISTRICT 12 MEDICAL EXAMINER CASE NUMBER: 21-02238-S
OSTEOLOGICAL EXAMINATION CASE NUMBER: 10G21
NORTH PORT POLICE DEPARTMENT CASE NUMBER: 21-054011
FEDERAL BUREAU OF INVESTIGATION CASE NO.: 70A-DN-3494764

DATE AND MODE OF RECEIPT OF REMAINS: On 22 October 2021, I accepted receipt of these skeletal remains directly from the District 12 Office of the Medical Examiner. At the request of the medical examiner, I conducted an osteological analysis of identification and trauma. All analyses were conducted within the secure laboratory space provided to me within the District 20 Office of the Medical Examiner (3838 Domestic Avenue, Naples, Florida 34104). According to information provided by medical examiner personnel, this decedent was positively identified via dental comparison as Mr. Brian Laudrie (born 18 November 1997).

CASE NARRATIVE: At the request of the District 12 Medical Examiner's Office, I reported to the discovery location (6968 Reistertown Road, North Port, Florida, 34286) on 21 October 2021 at approximately 1:00pm. Florida Gulf Coast University Human Identity and Trauma Analysis (HITA) Laboratory Coordinator, Micki David, M.S., accompanied me.

Upon my arrival, FBI-Special Agent Loretta Bush escorted Ms. David and I through the scene highlighting the areas (Zones 1, 2, and 3) where human and possible nonhuman remains had been discovered and flagged. I identified the nonhuman skeletal remains which were collected by the FBI. I reviewed *in situ* and specimen photographs of the human remains to create a preliminary skeletal inventory while at the scene. At my request, each zone was excavated to sterile soil (approximately 6cm deep) using clean Marshalltown trowels, Fiskar clippers, dust pans, and flat shovels. All of the leaf litter and soil was placed into clean 5-gallon buckets and sifted through ¼ inch screens onto a tarp (Figures 1 & 2). This process led to the discovery of nine cranial fragments, two maxillary central incisors, and one distal hand phalange. On 22 October 2021, I attended the autopsy and assisted the medical examiner with the skeletal inventory. On the same day, I accepted receipt of these remains for subsequent analysis.

ESTIMATION OF POSTMORTEM INTERVAL: According to information provided by medical examiner and law enforcement personnel, this decedent left his home on 13 September 2021. A missing person report was filed on 17 September 2021. Upon my initial examination, these remains were skeletonized and lacked the odor of decomposition. Small amounts of thin, dry cartilage were observed on many of the long bone joint surfaces, auricular surfaces of the *ossa coxae* and sacrum, and vertebrae. Dry adipocere was observed on elements of the hands and feet. These observations informed my estimation of postmortem interval. The postmortem interval was estimated using a submerged remains equation following Heaton and colleagues (2010). With water temperature data from the Shakett Creek USGS station (mean water

temperature = 28.9°C¹) and a total aquatic decomposition score for these remains (TADS = 8), the postmortem interval was 47.4 days to 672.4 days (or approximately a 1½ months to nearly two years) (Appendix B). I also calculated a postmortem interval using the Vass (2011) equation for surface scattered remains. Using an average ambient temperature (26.1°C²), average humidity (79.6%), and maximum decomposition score, the maximum postmortem interval of 60.05 days was produced (Appendix B). These findings must be interpreted with caution because these studies have not been adequately tested in Florida.

SKELETAL INVENTORY & MINIMUM NUMBERS OF INDIVIDUALS: This individual was remarkably complete (Figure 3; Appendix B). The cranium was fragmentary and comprised 35 fragments. The cranium was reconstructed using Duco cement. Post reconstruction, eight cranial fragments (ranging in size from 2cm – 4cm in maximum diameter) from the sphenoid and orbital plate of the frontal could not be re-attached. All of the remains present for analysis were morphologically consistent without irregular duplication. These were the remains of one individual (Figure 3). In addition to the human skeletal remains that were analyzed, nonhuman remains were also recovered (Figure 4). Specifically, the incomplete skeletons of two *Sus scrofa* (Boar) and one metapodial from *Bos taurus* (Cow/Bull) were present (n = 135 elements) (Appendix B).

AGE: Macroscopic analysis of these remains was conducted to estimate biological skeletal age-at-death. The following age-related changes were observed:

- All secondary centers of ossification were completely fused which indicated that this decedent was an adult (Figure 3) (Cunningham et al. 2016).
- The midline and lateral cranial sutures were evaluated following Meindl and Lovejoy (1985). The method produced age ranges of 28 – 44 years (mean age = 36 years) and 20 – 42 years (mean age = 31 years) for the midline and lateral sutures, respectively.
- The incisive suture was evaluated following Mann and colleagues (1987) and consistent with an age of ≥ 25 years.
- The morphology of the sternal end of the right 4th rib was consistent with Iscan and colleagues' (1984) Stage 3 (age range = 24 – 28 years; mean age = 26 years).
- The pubic symphysis was most similar to Suchey-Brooks' Male (1990) Phase 2 (age range = 19 – 34 years; mean age = 26.5 years) (Figure 5).
- The auricular surfaces were most consistent with Lovejoy et al.'s (1985) Stage 2 (age range = 25 – 29; mean age = 27 years) (Figure 5).

ADBOU 2.1 transitional analysis was conducted using the analyses of the cranial sutures, pubic symphyses, and auricular surfaces. The program calculated an age range of 16.3 – 25.1 years

¹ For 13 September through 20 October 2021.

² Weather data was averaged from 13 September through 20 October 2021 for the Glenridge Palmer Ranch weatherSTEM station in Sarasota county.

(point estimate = 20.6 years, corrected) for white males (Milner et al. 2002) (Appendix B). This finding was consistent with Mr. Brian Landrie who was 23 years old.

SEX: Nonmetric and metric analysis was conducted to estimate biological skeletal sex. The following male traits were observed on the cranium: large mastoid processes, blunt supraorbital margin, pronounced glabella, well-developed nuchal region with inion hook, and robust mental eminence (Figure 6, Appendix B) (Walker 2008). The *ossa coxae* presented with the following male traits: narrow subpubic angle and greater sciatic notch, tall and narrow ilium, absent ventral arc, and narrow pelvic inlet (Figure 7, Appendix B) (Klales 2012). Statistical analysis of these qualitative data estimated that these skeletal remains were male (Appendix B). Metric assessment using FORDISC 3.1 (Ousley & Jantz, 2012) supported the nonmetric findings (Posterior probability_{cranial} = 0.722, F typicality probability_{cranial} = 0.444, Chi typicality probability_{cranial} = 0.424, R typicality probability_{cranial} = 0.509); (Posterior probability_{postcranial} = 0.692, F typicality probability_{postcranial} = 0.743, Chi typicality probability_{postcranial} = 0.732, R typicality probability_{postcranial} = 0.745) (Appendix C). This finding was consistent with the biological description of Mr. Brian Landrie.

ANCESTRY: Nonmetric and metric analysis was conducted to estimate skeletal ancestry. The cranium presented with a long nasal spine, patent nasal sill, narrow nasal aperture, angled nasals, s-shaped zygomaticomaxillary sutures, Carabelli's cusps, anterior bulging transverse palatine sutures and simple vault sutures (Figure 6)³. Statistical analysis of these qualitative data estimated that this decedent was white (Appendix B) (Hefner 2009). Metric assessment of the cranium using FORDISC 3.1 (Ousley & Jantz, 2012) supported the nonmetric findings (Posterior probability = 0.639, F typicality probability = 0.621, Chi typicality probability = 0.592, R typicality probability_{cranial} = 0.564) (Appendix C). This finding was consistent with the biological description of Mr. Brian Landrie.

STATURE: Forensic stature was estimated using FORDISC 3.1 (Jantz & Ousley 2012) and measurements of the radius (maximum length = 264mm) and ulna (maximum length = 277mm)⁴. The program calculated forensic stature for white male ancestry groups using a 95% confidence interval as 66.2 – 74.9 inches or approximately 5'6" – 6'2" (Appendix C). This finding was consistent with the known biological description of Mr. Brian Landrie, who was reportedly 5'8" tall.

DENTAL INVENTORY & IDIOSYNCRATIC TRAITS: Gross, radiographic, and microscopic examination (using a zoom stereomicroscope EMZ – 13 1.0X – 7.0X) was conducted to evaluate the dentition. The following was observed:

- Marked dental calculus was observed with the most severe form on teeth 23 – 27.
- Teeth 1 and 16 (the maxillary 3rd molars) were impacted.
- Teeth 17 and 18 had small occlusal caries.
- Teeth 23 – 26 evidenced dental crowding.
- The central maxillary incisors, teeth 8 and 9, were labially displaced (procumbent).
- Teeth 4, 6, 7, 10, 11, and 29 were lost postmortem.

³ The morphology of the orbits and zygomatics was difficult to assess because of fragmentation.

⁴ The femora, tibiae, and humeri were incomplete. Consequently, the radius and ulna were used to estimate stature.

ANTEMORTEM PATHOLOGIC CHANGE: Gross, radiographic, and microscopic examination (using a zoom stereomicroscope EMZ – 13 1.0X – 7.0X) of the skeletal remains revealed the following antemortem pathological change:

- A Schmorl's node (e.g., a herniation of the *nucleus pulposus* into the *annulus fibrosus*) was observed on the superior body of T12 (Mann et al. 2016).
- Accessory facets marked the spinous processes of T6 – T8 (Figure 8).
- Axial development defects were observed and included a bifurcated superior facet on C1, sternal aperture, and asymmetry of the first coccygeal segment (Figures 8 & 9).
- Asymmetry of the mandibular rami and condyles was observed (an axial developmental defect) with the right mandibular ramus being approximately 12mm shorter than the left (Figure 8).
- The clavicles were asymmetrical with the right being approximately 10mm shorter than the left (Figure 9).
- The clavicular origin for the deltoideus muscle was more pronounced on the left than the right.
- Costal cartilage calcifications were observed on the right and left ribs 7 – 10.

PERIMORTEM TRAUMA: Gross and radiographic analysis revealed perimortem gunshot trauma to the cranium that separated the neurocranium from the facial skeleton along the supraorbital margin (Figures 10 – 13). Radiating fractures were observed on most of the cranial bones. The fracture margins throughout the cranium were homogenous in color. The frontal, left parietal, left temporal, and left superior wing of the sphenoid presented with extensive fracturing and loss of bone (Figures 10 – 13). The right parietal evidenced a near circular defect with focal radiating fractures and focal bone loss. The anterior to posterior maximum diameter of the defect was 12mm as measured on the endocranial surface. Stellate fracturing traveled from the near circular defect and marked the right temporal, right greater wing of the sphenoid, and frontal. The pneumatic bones of the cranial base including the temporal petrous pyramids, basilar portions of the occipital, and body of the sphenoid were fractured. Diastatic fractures marked the right frontozygomatic suture, right and left zygomaticotemporal sutures, transverse palatine suture, and left occipito-temporal suture. The postmortem radiography did *not* reveal radio-opacities consistent with bullet fragmentation (Figure 13).

TAPHONOMY: Gross, radiographic, and microscopic examination (using a zoom stereomicroscope EMZ – 13 1.0X – 7.0X) of the skeletal remains revealed taphonomic change. Specifically, postmortem taphonomic change included evidence of carnivore scavenging (e.g., pits, punctures, and scoring) and rodent scavenging (e.g., parallel scoring) damage (Appendix B; Figures 14 & 15). Postmortem staining of the cortical and trabecular bone ranged in color from dark yellowish brown to reddish brown throughout these remains that was consistent with the tannic soils and water of the Myakkahatchee wetlands. Isolated patches of black and red

discoloration, consistent with fungi/mold was observed on the bones of the lower extremity (Appendix B). White coloration from adherent adipocere was also observed and consistent with decomposition in a wet environment.

SUMMARY: The forensic osteological analysis for medical examiner case 21-02238-S revealed that these skeletal remains were consistent with Mr. Brian Landrie. Antemortem skeletal evidence included a Schmorl's node, accessory facets on the spinous process of T6 – T8, axial developmental defects (i.e., sternal foramen, bifurcated C1 facet, asymmetrical mandibular rami and condyles, and coccyx), costal cartilage calcification, and asymmetrical clavicles. The cranium evidenced fracturing consistent with perimortem gunshot trauma. Postmortem taphonomic change included evidence of scavenging and bone discoloration consistent with decomposition on the soils and within the waters of the Myakkahatchee wetlands.

ATTACHMENTS: Appendices A (Photographs), B (Tables & Figures), C (FORDISC output), and D (Literature cited) are attached.



Heather Walsh-Haney, Ph.D., D-ABFA #131, F-AAFS

Chair, Department of Justice Studies

Associate Professor

Florida Gulf Coast University

10501 FGCU Boulevard South

Fort Myers, Florida 33965-6565

Office Phone: (239) 590-7693

Email: hwalsh@fgcu.edu

DATE: 8 November 2021

REPORT DIRECTED TO:

Wilson "Tony" Broussard, M.D.

Deputy Chief Medical Examiner

District 12 Office of the Medical Examiner

2001 Siesta Drive, Suite 302

Sarasota, Florida 34239

APPENDIX A

Figures

The photographs in this appendix have been redacted in accordance with Florida Statute 406.135. Therefore, they are not part of the public record. The report containing the photographs within Appendix A is on file at the District 12 Office of the Medical Examiner.




Figure 1: Overall image (provided by North Port Police Department) depicting the scene upon arrival on Day 2 for medical examiner case 21-02238-S.




Figure 2: Overall image (provided by North Port Police Department) depicting the scene at the end of Day 2 for medical examiner case 21-02238-S.




Figure 3: Overall photograph depicting the remains associated with medical examiner case 21-02238-S in anatomical position.



Figure 4: Overall photograph of the nonhuman remains from the scene associated with medical examiner case 21-02238-S. The blue arrow highlights the *Bos taurus* (Cow/Bull) metapodial.




Figure 5: From left to right, pubic symphysis and auricular surfaces used for the estimation of biological skeletal age-at-death for medical examiner case 21-02238-S.




Figure 6: Left lateral (left), anterior (middle), and right lateral (right) views of the skull, used for the estimation of biological skeletal age, sex, and ancestry for medical examiner case 21-02238-S.



Figure 7: Superior (left) and anterior (right) views of the pelvic girdle used to estimate biological skeletal sex for medical examiner case 21-02238-S.




Figure 8: Sternal foramen (left) and accessory facets on the spinous processes of T6 – T8 (blue arrows) for medical examiner case 21-02238-S.




Figure 9: Axial developmental defects including the bifurcated superior articular facet (left), asymmetrical clavicles (middle), and irregular mandibular condyles (right) for medical examiner case 21-02238-S.




Figure 10: Right lateral view of the cranium, depicting one gunshot defect with radiating fractures for medical examiner case 21-02238-S.




Figure 11: Right lateral view of the cranium, depicting one gunshot defect with radiating fractures for medical examiner case 21-02238-S.




Figure 12: Superior (left), posterior (middle), and inferior (right) views of the cranium, depicting radiating fractures from both (lateral) gunshot defects for medical examiner case 21-02238-S.




Figure 13: Left (left) and right (right) lateral postmortem radiographs of the skull evaluated for ante-, peri-, and postmortem change for medical examiner case 21-02238-S.



Figure 14: From left to right, anterior overall views of the humeri, ulnae, radii, femora, tibiae, and fibulae, which illustrated carnivore scavenging.




Figure 15: The proximal femoral epiphysis with carnivore scavenging damage evidenced by pits, punctures, and scoring for medical examiner case 21-02238-S.

**APPENDIX B
Tables & Figures**

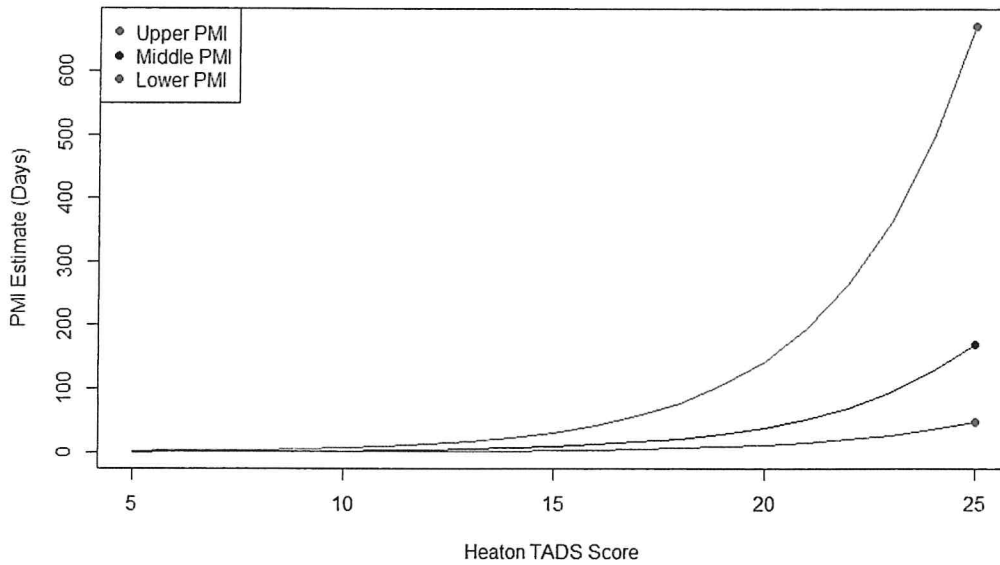


Figure 16: Postmortem Interval (PMI) estimation in days (28.9°C) using the Heaton and colleagues (2010) equation as applied to the medical examiner case 21-02238-S is presented.

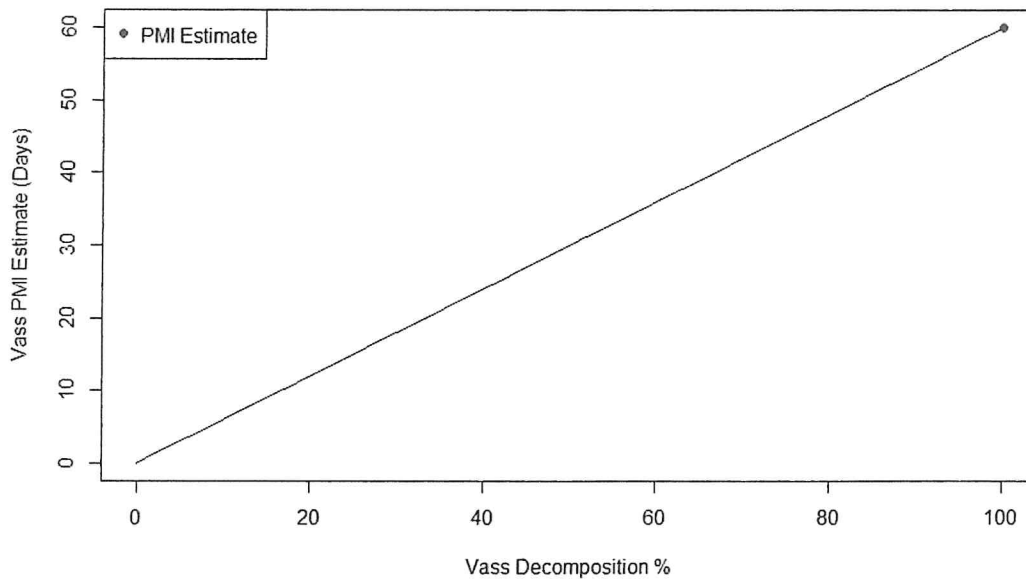


Figure 17: The Vass (2011) Aerobic Decomposition PMI estimate (Temperature = 26.1°C, Humidity = 79.6%) as applied to the medical examiner case 21-02238 is presented.

Table 1: Quantity and completeness of skeletal elements associated with medical examiner case 21-02238-S following Buikstra and Ubelaker (1994) with completeness scored as 0 = absent, 1 = >75%, 2 = 25-75%, 3 = <25%. The word "all" indicates every bone on the line was represented by the completeness number.

Element	Side	Quantity	Completeness
Frontal	-	1	1
Parietal	Right & Left	2	1 (all)
Temporal	Right & Left	2	1 (all)
Occipital	-	1	1
Sphenoid	-	1	2
Zygomatic	Right & Left	2	1 (all)
Maxillae	Right & Left	2	1 (all)
Maxillary teeth	Right & Left	11	1 (all)
Palatine	Right & Left	2	1 (all)
Mandible	-	1	1
Mandibular teeth	Right & Left	15	1 (all)
Ethmoid	-	0	0
Lacrimal	Right & Left	0	0 (all)
Nasals	Right & Left	2	1 (all)
Nasal concha	Right	0	0
Nasal concha	Left	1	3
Vomer	-	1	3
Hyoid	-	0	0
Thyroid & cricoid cartilage	-	0	0
Manubrium	-	1	1
Sternal body	-	1	1
Xiphoid process	-	0	0
Rib	Right & Left	24	1 (all)
Clavicle	Right & Left	2	1 (all)
Scapula	Right & Left	2	1 (all)
Humerus	Right & Left	2	1 (all)
Ulna	Right	1	1
Ulna	Left	1	2
Radius	Right & Left	2	1 (all)
<i>Os coxa</i>	Right & Left	2	1 (all)
Femur	Right & Left	2	1 (all)
Tibia	Right & Left	2	1 (all)
Fibula	Right & Left	2	1 (all)
Patella	Right & Left	0	0 (all)
C1 – C7	-	7	1 (all)
T1 – T12	-	12	1 (all)
L1 – L5	-	1	1 (all)
Sacrum	-	1	1
Coccyx (n = 1 segment)	-	1	1
Carpals 1 – 5	Right & Left	0	0
Metacarpal 1, 3, & 4	Left	0	0
Metacarpal 2 & 5	Left	2	1 (all)
Metacarpals 1, 2, 4, & 5	Right	4	1 (all)
Metacarpal 3	Right	0	0
Proximal Hand Phalange	-	4	1 (all)
Intermediate Hand Phalange	-	3	1 (all)
Distal Hand Phalange	-	1	1
Talus	Right & Left	0	0
Calcaneus	Right	0	0
Calcaneus	Left	1	1

Table 2: (continued): Quantity and completeness of skeletal elements associated with medical examiner case 21-02238-S following Buikstra and Ubelaker (1994) with completeness scored as 0 = absent, 1 = >75%, 2 = 25-75%, 3 = <25%. The word "all" indicates every bone on the line was represented by the completeness number.

Element	Side	Quantity	Completeness
Lateral cuneiform	Right	0	0
Lateral cuneiform	Left	1	1
Medial cuneiform	Right & Left	0	0
Intermediate cuneiform	Right & Left	0	0
Navicular	Right & Left	0	0
Metatarsal (1, 2, 4, 5)	Right	4	1 (all)
Metatarsal (3)	Right	0	0
Metatarsal (1 – 3)	Left	0	0
Metatarsal (4, 5)	Left	2	1
Proximal Foot Phalanges	-	1	1
Intermediate Foot Phalanges	-	0	0
Distal Foot Phalanges	-	0	0

Table 3: Nonhuman skeletal elements identified by species and quantity associated with medical examiner case 21-02238-S (adapted from Buikstra & Ubelaker 1994).

Species	Element	Side	Quantity
<i>Sus scrofa</i> (wild boar)	Cranium (containing 11 maxillary teeth)	-	1
	Loose teeth	-	1
	Mandible (containing 18 mandibular teeth)	-	1
	Tusks	-	2
	Metapodials	-	13
	Astragalus	-	2
	Calcaneus	-	1
	Phalanges	-	6
	Scapula	Left & Right	2
	C1		1
	C2		2
	C3		2
	C4		2
	C5		1
	C6		1
	C7		2
	Thoracic Vertebrae		22
	Lumbar Vertebrae		9
	Sacrum		1
	Vertebral Epiphyses		9
	Sternum		1
	Ribs		23
	<i>Os coxa</i>	Right & Left	2
	Humerus	Right & Left	2
	Radius	Left	1
	Radius	Right	2
	Ulna	Left	1
	Ulna	Right	2
	Radio-ulna	Left	1
	Femur	Left	1
	Tibia	Left	2
	Tibial Epiphysis	Right	1
	Miscellaneous Tibia	-	2
Miscellaneous Bone Fragments	-	10	
<i>Bos taurus</i> (cow)	Anterior Metapodial	-	1
Total Elements			135

Table 4: Sex estimation logistic regression equations for Walker (2008) for the skull for medical examiner case 21-02238-S.

Score	Sex	Prob M	Prob F	Accuracy
-7.087	Male	1.00	0.00	88/86
-6.242	Male	1.00	0.00	85/83
-6.193	Male	1.00	0.00	87/82
-4.794	Male	0.99	0.01	70/84
-5.41	Male	1.00	0.00	78/78
-4.407	Male	0.99	0.01	77/83

Scores for the nuchal region = 5; mastoid = 4, orbit = 3; glabella = 5, and mental eminence = 3.

Table 5: Sex linear discriminant functions for Kiales et al (2012) for the pelvis for medical examiner case 21-02238-S.

Score	Sex	Prob M	Prob F	Accuracy	Vars
-3.423	Male	0.97	0.03	92/97	MV
-5.31	Male	1.00	0.00	89/98	SMV
-3.231	Male	0.96	0.04	88/98	SV
-6.128	Male	1.00	0.00	87/96	SM
2.228	Male	0.90	0.10	98/74	SMV

Table 6: OSSA scoring following Hefner (2009) for medical examiner case 21-02238-S.

	ANS Score	Ossa Score	Summed Score
Anterior Nasal Spine	3	1	-
Nasal Aperture Width	2	1	-
Inferior Nasal Aperture	4	1	-
Nasal Bone Contour	4	1	-
Interorbital Breadth	1	1	-
Post-Bregmatic Depression	0	1	-
Summed Score	-	-	6

Table 7: Carnivore scavenging damage on the postcranial elements identified by skeletal element and the size of the punctures and pits associated with medical examiner case 21-02238-S.

Bone	Side	Proximal & Distal	Size (mm; minimum diameter)
Humerus	Right	Proximal	2.01 – 2.36
Radius	Right	Distal	1.22 – 2.28
Metacarpal 2	Left	Proximal	1.87 – 2.28
Femur	Right	Proximal & Distal	1.42 – 1.79
Femur	Left	Proximal & Distal	2.15 – 2.29
Tibia	Right	Proximal	2.01 – 2.19
Tibia	Left	Proximal	1.84 – 1.89
Fibula	Right	Proximal & Distal	2.03 – 2.30
Metatarsal 5	Right & Left	Proximal & Distal	1.64 – 2.15

Table 8: Bone discoloration depicting hue, value, chroma, and color (Munsell 2009) for the skeletal remains associated with medical examiner case 21-02238-S.

Color	Hue	Value	Chroma	Associated Elements
White	White	N	9.5	Slight adipocere, throughout remains
Dark Yellowish Brown	10YR	3	4	Throughout remains
Very Pale Brown	10YR	7	3	T1 – T10 (spinous processes); right ribs 3, 8, and 10; and left ribs 6 – 8 (visceral surfaces)
Red	7.5R	5	8	Proximal tibia
Very Dark Brown	10YR	2	2	Right femoral shaft and distal left humerus
Very Dark Grey	10YR	3	1	T1 – T3, T9 – L5 (vertebral foramen)
Black	10YR	2	1	Right proximal tibia; left distal tibia; right distal femur

APPENDIX C FORDISC OUTPUT

FORDISC 3.1.315 Analysis of 21-02238-S Excluded from samples: ID = F0122, F2620, F1181, F1686, F1995, F3017, SI243775, F2613, SI225085, F0963, F2678, B71, F1612, F1904, F2040, F0932, F2154 Using cranial data file version 1.23 DFA results using 16 measurements: ASB BBH BNL BPL FOL MAB MAL MDH NLB NLH OBB OBH OCC PAC UFHT XCB Measurements removed: FOB

Measurement Checks and Group Means

21-02238-S	Chk	Group Means															
		AF 25	AM 45	BF 39	BM 61	CHM 74	GTM 69	HF 30	HM 144	JF 112	JM 182	VM 46	WF 123	WM 227			
ASB	119	+	106.9	111.5	107.3	111.6	106.9	108.8	107.9	109.7	104.3	107.6	105.3	109.9	114.7		
BBH	135		129.1	133.1	131.2	138.0	139.5	133.2	130.1	136.2	132.0	138.2	137.7	134.2	141.3		
BNL	106		99.5	102.7	98.6	104.5	100.6	98.4	95.2	100.6	95.5	101.6	97.5	98.8	106.1		
BPL	103		96.4	99.9	99.4	103.9	96.0	97.9	92.6	98.1	93.7	97.5	95.6	92.2	98.2		
FOL	38	+	36.4	36.6	35.1	36.9	35.7	35.6	35.7	36.5	34.5	35.9	34.4	35.7	37.6		
MAB	60		62.7	66.0	63.0	66.5	64.1	64.6	62.2	65.0	60.3	63.9	66.3	57.9	61.3		
MAL	52		53.2	54.7	56.1	58.0	52.8	55.1	51.9	55.3	50.5	52.7	52.2	51.3	54.6		
MDH	36	+	24.7	29.1	28.5	33.1	29.5	31.1	25.8	28.4	26.2	30.1	26.4	27.8	32.3		
NLB	24		25.3	26.2	25.0	26.1	26.2	25.5	24.4	25.0	25.0	25.5	26.2	22.5	23.9		
NLH	50		51.9	53.6	48.5	52.2	52.4	51.9	48.7	52.0	48.8	51.4	52.9	48.6	52.8		
OBB	42		40.8	42.2	38.9	41.2	38.7	39.0	38.7	39.7	37.7	39.3	38.3	39.4	41.2		
OBH	34		35.2	35.0	34.5	35.1	33.7	36.2	35.4	35.3	33.8	34.1	33.8	33.1	34.1		
OCC	97		93.5	93.8	97.4	99.6	98.3	95.5	95.1	96.8	96.7	100.1	98.3	97.4	100.7		
PAC	123	+	107.4	109.3	112.6	117.3	115.3	112.3	108.0	111.7	109.0	113.3	110.3	112.6	118.0		
UFHT	73		71.2	73.3	67.8	72.8	73.1	71.8	67.3	73.3	68.4	72.1	71.2	66.7	72.4		
XCB	142		137.0	143.4	133.2	136.4	139.5	136.6	133.3	138.1	134.0	138.2	140.3	136.1	140.0		

+/- measurement deviates higher/lower than all group means; +/- deviates 1 to 2 STDEVS
 +/+/- deviates two to three STDEVS; +/+/- deviates at least 3 STDEVS

Natural Log of VCVM Determinant = 36.2944

Classification Table

From Group	Total Number	Into Group (counts)													Correct
		AF	AM	BF	BM	CHM	GTM	HF	HM	JF	JM	VM	WF	WM	
AF	25	12	6	1	0	0	0	3	1	2	0	0	0	0	48.0 %
AM	45	6	24	2	2	3	0	1	2	1	2	1	0	1	53.3 %
BF	39	1	0	20	1	0	5	3	2	2	2	0	2	1	51.3 %
BM	61	0	2	5	28	1	9	1	4	1	2	0	0	8	45.9 %
CHM	74	0	2	0	4	30	2	1	6	4	16	5	3	1	40.5 %
GTM	69	2	2	5	6	1	33	4	7	1	5	1	2	0	47.8 %
HF	30	3	0	4	0	0	1	11	2	4	0	1	4	0	36.7 %
HM	144	14	3	8	12	10	16	10	34	7	11	5	4	10	23.6 %
JF	112	4	0	5	1	2	2	14	5	66	6	6	1	0	58.9 %
JM	182	4	9	11	16	34	4	3	9	13	63	6	3	7	34.6 %
VM	46	0	0	0	0	4	1	0	1	6	2	32	0	0	69.6 %
WF	123	4	3	3	0	1	0	5	2	3	1	0	84	17	68.3 %
WM	227	0	11	1	11	5	2	1	2	0	7	1	22	164	72.2 %

Total Correct: 601 out of 1177 (51.1 %) *** CROSS-VALIDATED ***

Multigroup Classification of 21-02238-s

Group	Classified into	Distance from	Probabilities			
			Posterior	Typ F	Typ Chi	Typ R
WM	**WM**	16.4	0.722	0.444	0.424	0.509 (112/228)
BM		19.7	0.142	0.266	0.236	0.339 (41/62)
JM		22.0	0.044	0.158	0.142	0.120 (161/183)
WF		22.2	0.039	0.153	0.136	0.081 (114/124)
AM		22.5	0.034	0.154	0.127	0.304 (32/46)
HM		25.4	0.008	0.074	0.063	0.193 (117/145)
GTM		27.6	0.003	0.045	0.035	0.100 (63/70)
BF		27.8	0.002	0.046	0.034	0.050 (38/40)
CHM		27.9	0.002	0.041	0.032	0.040 (72/75)
AF		28.5	0.002	0.043	0.028	0.077 (24/26)
JF		30.1	0.001	0.022	0.017	0.018 (111/113)
HF		32.6	0.000	0.014	0.008	0.097 (28/31)
VM		43.6	0.000	0.000	0.000	0.021 (46/47)

21-02238-s is closest to WMs

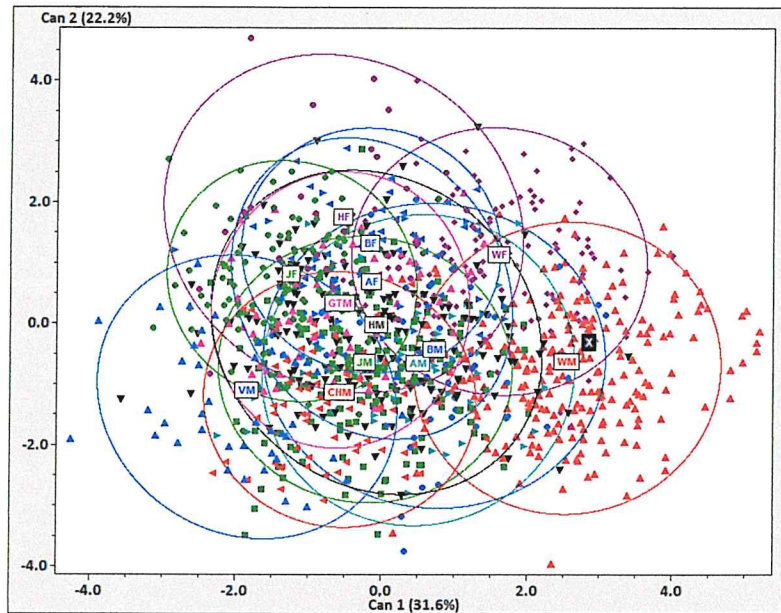


Figure 18: Canonical distribution of the FORDISC 3.1 statistical output associated with medical examiner case 21-02238-S.

 FORDISC 3.1.315 Analysis of 21-02238-S Excluded from samples: ID = F2869, F2908, F2910, F1140, F2285, F1678, F0716, F0761, F2265, F2845, F3056, F0792 Using postcranial data file version 1.18 DFA results using 9 measurements: CLAXLN FEMHDD HUMHDD ILIABR INNOHT SACABR SACS1B ULNCIR ULNPHL

Measurement Checks and Group Means

		Group Means			
		BF	BM	WF	WM
21-02238-S	Chk	25	48	139	313
CLAXLN	158	139.4	158.3	139.3	157.3
FEMHDD	49 +	41.0	46.9	42.3	48.2
HUMHDD	47	40.2	46.8	42.6	49.0
ILIABR	155	141.5	154.2	156.6	162.1
INNOHT	220	187.3	211.6	203.6	224.2
SACABR	111 +	100.5	103.5	109.5	108.7
SACS1B	53 +	44.0	50.7	46.0	51.1
ULNCIR	33	32.1	36.9	31.7	36.5
ULNPHL	245	220.8	256.2	216.2	240.1

 +/- measurement deviates higher/lower than all group means; +/--- deviates 1 to 2 STDEVs; +++/--- deviates two to three STDEVs; ++++/--- deviates at least 3 STDEVs

Natural Log of VCVM Determinant = 27.7079

 Classification Table

From Group	Total Number	Into Group (counts)				Correct
		BF	BM	WF	WM	
BF	25	22	1	2	0	88.0 %
BM	48	3	44	0	1	91.7 %
WF	139	9	0	129	1	92.8 %
WM	313	3	21	14	275	87.9 %

 Total Correct: 470 out of 525 (89.5 %) *** CROSS-VALIDATED ***

 Multigroup Classification of 21-02238-S

Group	Classified into	Distance from	Probabilities			
			Posterior	Typ F	Typ Chi	Typ R
WM	**WM**	6.1	0.692	0.743	0.732	0.745 (80/314)
BM		7.7	0.307	0.593	0.565	0.653 (17/49)
BF		19.5	0.001	0.033	0.021	0.038 (25/26)
WF		22.3	0.000	0.010	0.008	0.043 (134/140)

 21-02238-S is closest to WMs

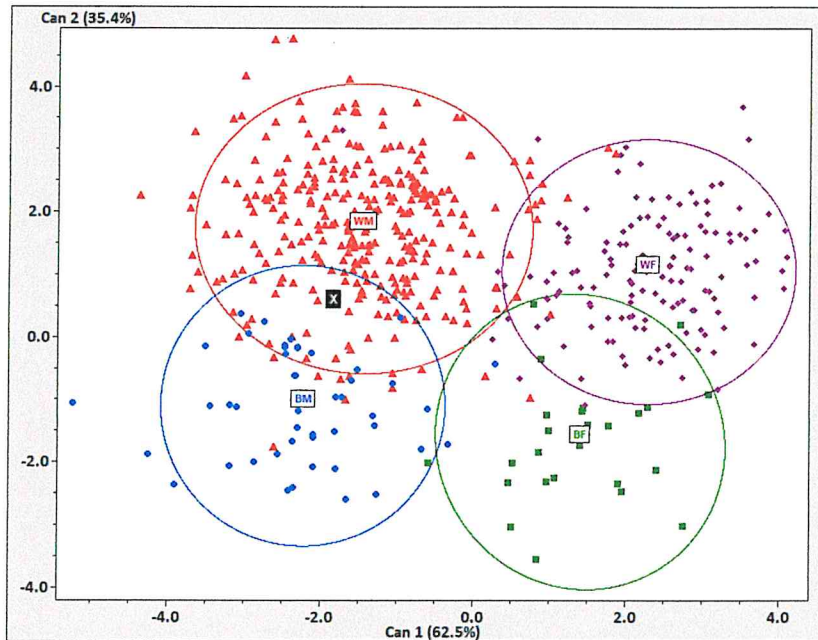


Figure 19: Canonical distribution of the FORDISC 3.1 statistical output associated with medical examiner case 21-02238-S.

FORDISC 3.1.315 Analysis of 21-02238-S Excluded from samples: ID = F0122, F1548, F1995, F2620, F3366, F3017, F1321, F1741, SI225085, F1686, F2504, F2678, F2680 Using cranial data file version 1.23 DFA results using 16 measurements: BBH BNL BPL EKB FOL MAB MAL MDH NLB NLH OBB OBH OCC PAC UFHT XCB

Measurement Checks and Group Means

			Group Means			
			AM	BM	HM	WM
21-02238-s	Chk	49	108	177	297	
BBH	135		133.5	137.7	136.7	141.7
BNL	106		103.0	104.8	100.9	106.2
BPL	103		100.0	104.4	98.4	98.3
EKB	101		101.3	100.0	96.3	97.7
FOL	38	+	36.6	36.6	36.5	37.5
MAB	60	-	66.2	66.3	65.1	61.6
MAL	52	-	54.7	58.0	55.3	54.5
MDH	36	+	29.4	32.3	28.6	32.3
NLB	24		26.2	26.0	24.9	23.8
NLH	50	-	53.6	52.3	52.1	52.8
OBB	42		42.2	40.6	39.8	41.1
OBH	34		34.9	35.0	35.2	33.8
OCC	97		93.9	98.6	97.5	101.0
PAC	123	+	109.9	117.0	111.8	118.2
UFHT	73		73.2	72.5	72.9	71.8
XCB	142		143.3	135.8	138.3	140.1

+/- measurement deviates higher/lower than all group means; +/--- deviates 1 to 2 STDEVs; +++/-- deviates two to three STDEVs; ++++/-- deviates at least 3 STDEVs; Natural Log of VCVM Determinant = 37.5527

Classification Table

From Group	Total Number	Into Group (counts)				Correct
		AM	BM	HM	WM	
AM	49	34	4	9	2	69.4 %
BM	108	7	73	19	9	67.6 %
HM	177	14	27	115	21	65.0 %
WM	297	17	21	17	242	81.5 %

Total Correct: 464 out of 631 (73.5 %) *** CROSS-VALIDATED ***

 Multigroup Classification of 21-02238-S

Group	Classified into	Distance from	Probabilities			
			Posterior	Typ F	Typ Chi	Typ R
WM	**WM**	14.1	0.639	0.621	0.592	0.564 (130/298)
BM		16.1	0.230	0.483	0.444	0.495 (55/109)
AM		17.7	0.106	0.394	0.343	0.360 (32/50)
HM		20.5	0.026	0.229	0.198	0.264 (131/178)

 21-02238-S is closest to WMs

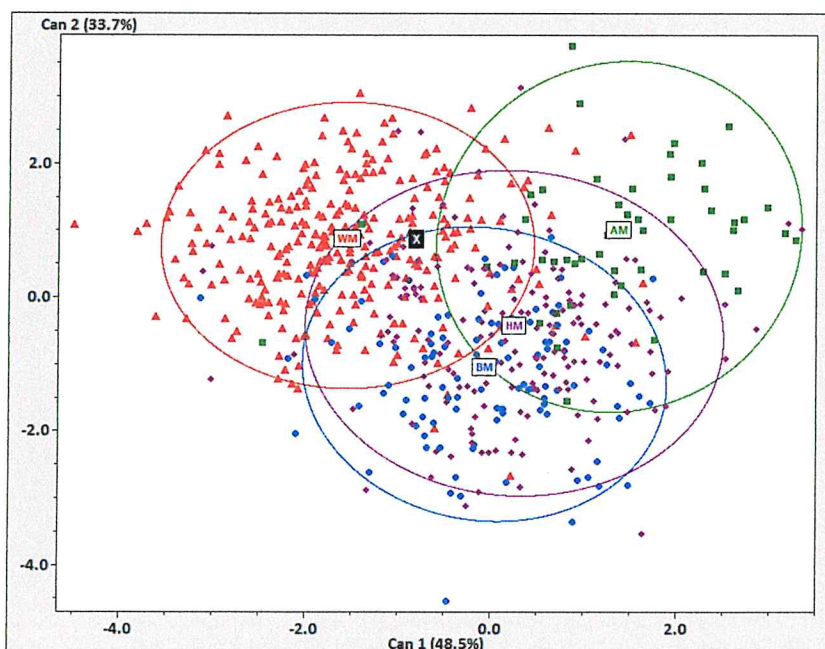


Figure 20: Canonical distribution of the FORDISC 3.1 statistical output associated with medical examiner case 21-02238-S.

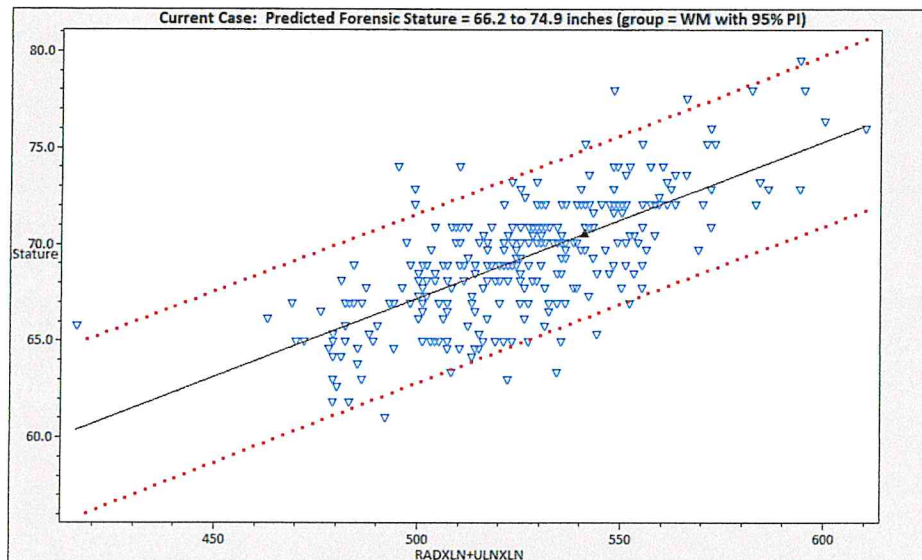


Figure 21: Stature estimation using FORDISC 3.1 for the remains associated with medical examiner case 21-02238-S.

**APPENDIX D
LITERATURE CITED**

- Brooks, S., & Suchey, J. M. (1990). Skeletal age determination based on the os pubis: a comparison of the Acsádi-Nemeskéri and Suchey-Brooks methods. *Human evolution*, 5(3), 227-238.
- Cunningham, C., Scheuer, L., & Black, S. (2016). *Developmental juvenile osteology*. Academic press.
- Galloway A. (1999). *Broken bones: anthropological analysis of blunt force trauma*: Charles C. Thomas Publisher.
- Heaton, V., Lagden, A., Moffatt, C., & Simmons, T. (2010). Predicting the postmortem submersion interval for human remains recovered from UK waterways. *Journal of forensic sciences*, 55(2), 302-307.
- Hefner, J. T. (2009). Cranial nonmetric variation and estimating ancestry. *Journal of forensic sciences*, 54(5), 985-995.
- Işcan, M. Y., Loth, S. R., & Wright, R. K. (1984). Metamorphosis at the sternal rib end: a new method to estimate age at death in white males. *American journal of physical anthropology*, 65(2), 147-156.
- Jantz, R. L., & Ousley, S. D. (2010). *FORDISC 3.0: personal computer forensic discriminant functions*. Knoxville, TN: University of Tennessee.
- Klales, A. R., Ousley, S. D., & Vollner, J. M. (2012). A revised method of sexing the human innominate using Phenice's nonmetric traits and statistical methods. *American journal of physical anthropology*, 149(1), 104-114.
- Lovejoy, C. O., Meindl, R. S., Pryzbeck, T. R., & Mensforth, R. P. (1985). Chronological metamorphosis of the auricular surface of the ilium: a new method for the determination of adult skeletal age at death. *American journal of physical anthropology*, 68(1), 15-28.
- Mann, R. W., Symes, S. A., & Bass, W. M. (1987). Maxillary suture obliteration: aging the human skeleton based on intact or fragmentary maxilla. *Journal of Forensic Science*, 32(1), 148-157.
- Mann, R. W., Hunt, D. R., & Lozanoff, S. (2016). *Photographic regional atlas of non-metric traits and anatomical variants in the human skeleton*. Charles C Thomas Publisher.
- Meindl, R. S., & Lovejoy, C. O. (1985). Ectocranial suture closure: A revised method for the determination of skeletal age at death based on the lateral-anterior sutures. *American journal of physical anthropology*, 68(1), 57-66.
- Milner, G. R., & Boldsen, J. L. (2012). Transition analysis: A validation study with known-age modern American skeletons. *American Journal of Physical Anthropology*, 148(1), 98-110.
- Munsell, A. H. (2009). *Munsell Soil Color Charts: X- Rite*.
- Vass, A. A. (2011). The elusive universal post-mortem interval formula. *Forensic science international*, 204(1-3), 34-40.
- Walker PL. (2008). Sexing skulls using discriminant function analysis of visually assessed traits. *Am J Phys Anthropol* 136:39–50.



Pinellas County Forensic Laboratory

10900 Ulmerton Road • Largo FL 33778 • (727) 582-6810 • Fax (727) 582-6822

Laboratory Report DNA Analysis

Lab Number: 21-008589

Request Number: 0001

Report Date: 11/19/2021

Request Date: 11/11/2021

Case Agency: District Twelve Medical Examiner
2001 Siesta Drive
Sarasota, FL, 34239

Case Number: 21-02238
Subject(s): Laudrie, Brian
Laudrie, Christopher
Laudrie, Roberta

Submission Date: 11/11/2021

Item 001 (Agency Item 1): Manila envelope sealed with evidence tape containing :

Item 001-A : one specimen cup containing one tooth (believed to be from Brian Laudrie).

Item 001-B : one specimen cup containing one section of the left proximal femur bone (believed to be from Brian Laudrie).

Item 001-C : one specimen cup containing one section of the left distal femur bone (believed to be from Brian Laudrie).

Submission Date: 11/16/2021

Item 002 (Agency Item 1): Manila envelope sealed with evidence tape containing one swab carton containing two buccal swabs from Christopher Laudrie.

Item 003 (Agency Item 2): Manila envelope sealed with evidence tape containing one swab carton containing two buccal swabs from Roberta Laudrie.

Results

Item 001-A - Tooth	Resulted in a DNA profile
Item 001-A - Tooth	Resulted in a DNA haplotype
Item 001-B - Section of left proximal femur	Resulted in a DNA profile
Item 001-B - Section of left proximal femur	Resulted in a DNA haplotype
Item 001-C - Section of left distal femur	Resulted in a DNA profile
Item 001-C - Section of left distal femur	Resulted in a DNA haplotype
Item 002 - Buccal swabs - Christopher Laudrie	Resulted in a DNA profile
Item 002 - Buccal swabs - Christopher Laudrie	Resulted in a DNA haplotype
Item 003 - Buccal swabs - Roberta Laudrie	Resulted in a DNA profile

Interpretations and Opinions

Item 001-A Tooth

DNA analysis of item 001-A [Tooth] resulted in a profile of a male individual.



Pinellas County Forensic Laboratory

10900 Ulmerton Road • Largo FL 33778 • (727) 582-6810 • Fax (727) 582-6822

Item 001-A Tooth *continued*

DNA analysis results from item 001-A [Tooth] were compared to those results developed from item 002 [Buccal swabs - Christopher Landrie] and item 003 [Buccal swabs - Roberta Landrie]. The DNA profile developed from item 001-A [Tooth] is consistent with having originated from the biological child of item 002 [Buccal swabs - Christopher Landrie] and item 003 [Buccal swabs - Roberta Landrie].

The DNA profile from item 001-A [Tooth] is 1.7 quintillion times more likely in the Caucasian population if this DNA profile is from a biological child of item 002 [Buccal swabs - Christopher Landrie] and item 003 [Buccal swabs - Roberta Landrie] than if the DNA profile is from a randomly selected individual unrelated to item 002 [Buccal swabs - Christopher Landrie] and item 003 [Buccal swabs - Roberta Landrie]. Statistical calculations are based on 21 of 21 STR loci.

Y-STR DNA analysis of item 001-A [Tooth] resulted in a haplotype.

The source of item 001-A [Tooth] is consistent with being a paternal male relative of item 002 [Buccal swabs - Christopher Landrie]. Paternal male relatives share the same haplotype profile barring any genetic mutations, thus, the source of item 002 [Buccal swabs - Christopher Landrie] cannot be excluded as the biological father of the source of item 001-A [Tooth].

The profile will be entered into the Combined DNA Index System (CODIS) in accordance with state and national regulations where regular searches will be performed.

Item 001-B Section of left proximal femur

DNA analysis of item 001-B [Section of left proximal femur] resulted in a partial profile of a male individual. This DNA profile is consistent with the DNA profile obtained from item 001-A [Tooth].

DNA analysis results from item 001-B [Section of left proximal femur] were compared to those results developed from item 002 [Buccal swabs - Christopher Landrie] and item 003 [Buccal swabs - Roberta Landrie]. The DNA profile developed from item 001-B [Section of left proximal femur] is consistent with having originated from the biological child of item 002 [Buccal swabs - Christopher Landrie] and item 003 [Buccal swabs - Roberta Landrie].

The DNA profile from item 001-B [Section of left proximal femur] is 3.9 quadrillion times more likely in the Caucasian population if this DNA profile is from a biological child of item 002 [Buccal swabs - Christopher Landrie] and item 003 [Buccal swabs - Roberta Landrie] than if the DNA profile is from a randomly selected individual unrelated to item 002 [Buccal swabs - Christopher Landrie] and item 003 [Buccal swabs - Roberta Landrie]. Statistical calculations are based on 19 of 21 STR loci.

Y-STR DNA analysis of item 001-B [Section of left proximal femur] resulted in a partial haplotype. This haplotype is consistent with the haplotype obtained from item 001-A [Tooth].

The source of item 001-B [Section of left proximal femur] is consistent with being a paternal male relative of item 002 [Buccal swabs - Christopher Landrie]. Paternal male relatives share the same haplotype profile barring any genetic mutations, thus, the source of item 002 [Buccal swabs - Christopher Landrie] cannot be excluded as the biological father of the source of item 001-B [Section of left proximal femur].

Item 001-C Section of left distal femur

DNA analysis of item 001-C [Section of left distal femur] resulted in a partial profile of a male individual. This DNA profile is consistent with the DNA profile obtained from item 001-A [Tooth].

DNA analysis results from item 001-C [Section of left distal femur] were compared to those results developed from item 002 [Buccal

Pinellas County Forensic Laboratory

10900 Ulmerton Road • Largo FL 33778 • (727) 582-6810 • Fax (727) 582-6822

Item 001-C Section of left distal femur *continued*

swabs - Christopher Landrie] and item 003 [Buccal swabs - Roberta Landrie]. The DNA profile developed from item 001-C [Section of left distal femur] is consistent with having originated from the biological child of item 002 [Buccal swabs - Christopher Landrie] and item 003 [Buccal swabs - Roberta Landrie].

The DNA profile from item 001-C [Section of left distal femur] is 170 trillion times more likely in the Caucasian population if this DNA profile is from a biological child of item 002 [Buccal swabs - Christopher Landrie] and item 003 [Buccal swabs - Roberta Landrie] than if the DNA profile is from a randomly selected individual unrelated to item 002 [Buccal swabs - Christopher Landrie] and item 003 [Buccal swabs - Roberta Landrie]. Statistical calculations are based on 18 of 21 STR loci.

Y-STR DNA analysis of item 001-C [Section of left distal femur] resulted in a partial haplotype. This haplotype is consistent with the haplotype obtained from item 001-A [Tooth].

The source of item 001-C [Section of left distal femur] is consistent with being a paternal male relative of item 002 [Buccal swabs - Christopher Landrie]. Paternal male relatives share the same haplotype profile barring any genetic mutations, thus, the source of item 002 [Buccal swabs - Christopher Landrie] cannot be excluded as the biological father of the source of item 001-C [Section of left distal femur].

Analyses Performed

Item 001-A - Tooth

Analysis Dates: 11/17/21 to 11/18/21

Prepfile BTA, QuantTrio, Globalfiler, YFiler Plus, CE

Item 001-B - Section of left proximal femur

Analysis Dates: 11/17/21 to 11/18/21

Prepfile BTA, QuantTrio, Globalfiler, YFiler Plus, CE

Item 001-C - Section of left distal femur

Analysis Dates: 11/17/21 to 11/18/21

Prepfile BTA, QuantTrio, Globalfiler, YFiler Plus, CE

Item 002 - Buccal swabs - Christopher Landrie

Analysis Dates: 11/18/21 to 11/18/21

Chelex, QuantTrio, Globalfiler, YFiler Plus, CE

Item 003 - Buccal swabs - Roberta Landrie

Analysis Dates: 11/18/21 to 11/18/21

Chelex, QuantTrio, Globalfiler, CE

Disposition

All items, including extracts, will be returned to the case or submitting agency for storage and final disposition. Extracts should be stored frozen.

Notes

This report contains the results, interpretations and/or opinions of the individual whose signature appears on the report. Some aspects of the analyses may have been conducted by other laboratory staff.

This report should not be reproduced, except in full, without written approval of the laboratory.

The results reflected on this report relate only to the items received and tested by the laboratory.

Pinellas County Forensic Laboratory

10900 Ulmerton Road • Largo FL 33778 • (727) 582-6810 • Fax (727) 582-6822

Beth Ordeman

Beth Ordeman, ABC-MB
DNA Analyst

< End of Report >

Pinellas County Forensic Laboratory

10900 Ulmerton Road • Largo FL 33778 • (727) 582-6810 • Fax (727) 582-6822

Appendix

Where applicable:

When the report reflects the determination of an "unknown individual," all analyzed samples from known individuals submitted in conjunction with this case have been excluded from the DNA profile.

GlobalFiler STR Analysis

DNA is extracted, quantitated, and amplified using the polymerase chain reaction (PCR).

The GlobalFiler STR loci are D3S1358, vWA, D16S539, CSF1PO, TPOX, Yindel, Amelogenin, D8S1179, D21S11, D18S51, DYS391, D2S441, D19S433, TH01, FGA, D22S1045, D5S818, D13S317, D7S820, SE33, D10S1248, DIS1656, D12S391, and D2S1338.

Binary Statistics (where applicable)

The National Institute of Standards and Technology (NIST) U.S population database, as published in Forensic Science International: Genetics, Volume 7, Issue 3, e82 - e83 and NIST 1036 Revised US Population Dataset (July 2017), <http://strbase.nist.gov/NISTpop.htm> were used to calculate STR statistics.

Any reported statistics associated with GlobalFiler STR results are an estimation for which a deviation of +/- 10 fold may exist.

A numerical designation for an unknown DNA profile (for example Unknown #1, Unknown #2) signifies that the statistics associated with the DNA profile reached the source attribution threshold.

Likelihood Ratio Statistics (where applicable)

STRmix™ software v2.6.3 was used to aid in DNA profile interpretation and for statistical calculations.

The National Institute of Standards and Technology (NIST) U.S population database, as published in Forensic Science International: Genetics, Volume 7, Issue 3, e82 - e83 and NIST 1036 Revised US Population Dataset (July 2017), <http://strbase.nist.gov/NISTpop.htm> were used in likelihood ratio calculations.

The likelihood ratios were calculated for the African American, Caucasian and Hispanic populations. The lowest 99% 1-SIDED LOWER HPD INTERVAL likelihood ratio was used for reporting.

The propositions presented in this report are based upon the case information provided. Additional propositions may impact the interpretations and results. If additional propositions should be considered, please contact the laboratory.

In DNA mixtures of closely-related individuals (such as parents, offspring, and siblings), false inclusions and/or exclusions of other closely-related family members can occur due to the similarity of genetic information between relatives.

Scale of verbal qualifiers for likelihood ratios:

<u>LR (H1 Support)</u>	<u>Verbal Qualifier</u>	<u>1/LR (H2 Support)</u>	<u>Verbal Qualifier</u>
1	Uninformative	1	Uninformative
2-1,000	Inconclusive	2-99	Limited support for exclusion
1,001-9,999	Moderate support for inclusion	100-999	Moderate support for exclusion
10,000-999,999	Strong support for inclusion	≥1,000	Exclusion
≥1,000,000	Very strong support for inclusion		

When H1 and H2 propositions are equal (LR=1) then the result is uninformative

Yfiler Plus STR Analysis

Yfiler Plus STR loci: DYS456, DYS389I, DYS390, DYS389II, DYS458, DYS19, DYS385a/b, DYS393, DYS391, DYS439, DYS635, DYS392, Y GATA H4, DYS437, DYS438, DYS448, DYS576, DYS627, DYS460, DYS518, DYS570, DYS449, DYS481, DYS387S1a/b and DYS533.

The YHRD database as published in Willuweit S., Roewer L. (2015), 'The new Y Chromosome Haplotype Reference Database.', Forensic Sci Int Genet 15, 43-8 [Pubmed] is used to calculate Y-STR statistics. A 95% confidence interval is applied to Yfiler Plus statistical calculations.

CODIS

A notification report will be issued any time there is a related hit in the Combined DNA Index System (CODIS) or any time that profile is removed from CODIS. Any non-entry into CODIS is due to existing similar CODIS entries, sample eligibility and/or data quality.

SAVE

Forensic Identification Report

Date: 10-21-2021

District 12 Medical Examiner case number: **ME 21-02238**

Introduction:

Nancy Havens, DDS Forensic Odontologist received a text and email October 20, 2021 at 11:36am, from David Winterhalter Detective from the office of the Medical Examiner District 12.

The Request: "We may need your services in a case tomorrow. Are you available?"

I responded: "yes tomorrow morning." David called me later with an 8 am scheduled time, at the Sarasota Memorial Morgue location.

District 12 Medical Examiner's office supplied Post-Mortem evidence.

1. Maxillae supplied intact and in good condition for examination.
#4,6,7,8,9,10,11 teeth missing from maxillae post- mortem loss; sockets open;
#1,2,3,5,12,13,14,15,16 in good condition for analysis;
Upper 3rd molars present with limited eruption and positioned with mesial inclinations.
2. Mandible supplied intact and in good condition for examination.
#29 tooth missing from mandible postmortem loss; socket open;
17,18,19,20,21,22,23,24,25,26,27,28,30,31,32 in good condition for analysis;
Lower 3rd molars present with eruption #17 distal inclination and #32 mesial inclinations.
3. Radiograph's taken by David Winterhalter and myself.
4. Pictures taken by Nancy L. Havens, DDS with a NIKON D100 Digital camera

Ante- Mortem Records supplied by:

Dr. Udeshi Sayville Family Dentistry
207 W. Main Street, Sayville, NY 11782 Office 631-589-0672 Cell 516-659-1167

The patient's last visit with Dr. Udeshi appears to be from the chart notes supplied 11/6/014; The patient was approximately 17 years old with adult dentition.

There was fully erupted dentition 2-15 and 17--32; and 1,16 molar impactions.
Orthodontic Treatment was completed 2-12-2010 per a letter in patient's chart dated 2-12-2010,
from Dr. LeonKempner & Dr. Davide Amfam

Discussion of comparisons:

1. There are several fully erupted teeth that had consistencies based on virgin teeth with root shapes that were identifiable on the radiographs taken post-mortem and compared with ante-mortem records.
#2,3,5,12,13,14,15,18,19,20,21,22,23,24,25,26,27,28,30,31
 - #2 distinct curve of mesial root toward the distal
 - #12 apical root has a slight curve to the distal ante-mortem and post-mortem
 - #13 apical root has a defined curve to the distal ante-mortem and post-mortem
 - #14 has wide spacing between the mesial-buccal & distal-buccal roots; lingual root is straight This is viewed both ante-mortem and post-mortem
 - #21 and #28 pulp stone seen ante-mortem and post-mortem
 - #30 has distinct trabeculae (bone pattern) seen ante-mortem and post-mortem between the divergent roots
 - There are many boney patterns that are consistent ante-mortem and post-mortem
 - Teeth 19-Bpit & 18-Bpit TX 12-20-11 with minimal decay and 31-Bpit no decay TX 12-20-11; all had reported composites placed which cannot be seen in the ante-mortem and post-mortem x-rays; this is typical of very small resin based fillings, they get hidden within the dense enamel structures of the tooth
 - Slight overlapping of the anterior teeth on the post-mortem but the shapes are similar to antemortem; this can happen after ORTHODONTIC TREATMENT, if the individual does not consistently wear a retainer.
2. Third Molars:
 - #1, #16 and #32 molars have a mesial- directed inclination ante-mortem and post-mortem
 - #1 and #2 are impacted
 - #17 has a slight distal inclination with an acute distal curve of the mesial root
 - #32 has three (3) very distinct fully developed roots consistent on ante-mortem and post-mortem
 - a. mesial root curves acutely to the distal at the apex
 - b. central root is straight
 - c. distal root curves gently toward the distal

The consistencies are the 24 teeth present post-mortem to be compared with ante-mortem records.

The distinctive features are: #1,2,12,13,14,16,17,21,28,30,32 and the intact bone to compare Root Relationships (proximities, angulation); Bone (height, trabeculae) and Sinuses.

Conclusion:

The fact that the Maxillae and Mandible are intact and I was able to make direct comparisons in this identification with x-rays and chart notes: **There is a high degree of certainty this victim is Brian Laundrie.**

The NCIC and my report are submitted by me Nancy Havens, DDS, MBA

I am available, at any time, to discuss this case. All remains, x-rays post-mortem and ante-mortem and photos are with the District 12 Medical Examiner's office.

Most Sincerely,

Nancy Havens DDS, MBA a practicing dentist & forensic odontologist

3839 Tangier Terrace Sarasota Florida 34239

941-356-2712